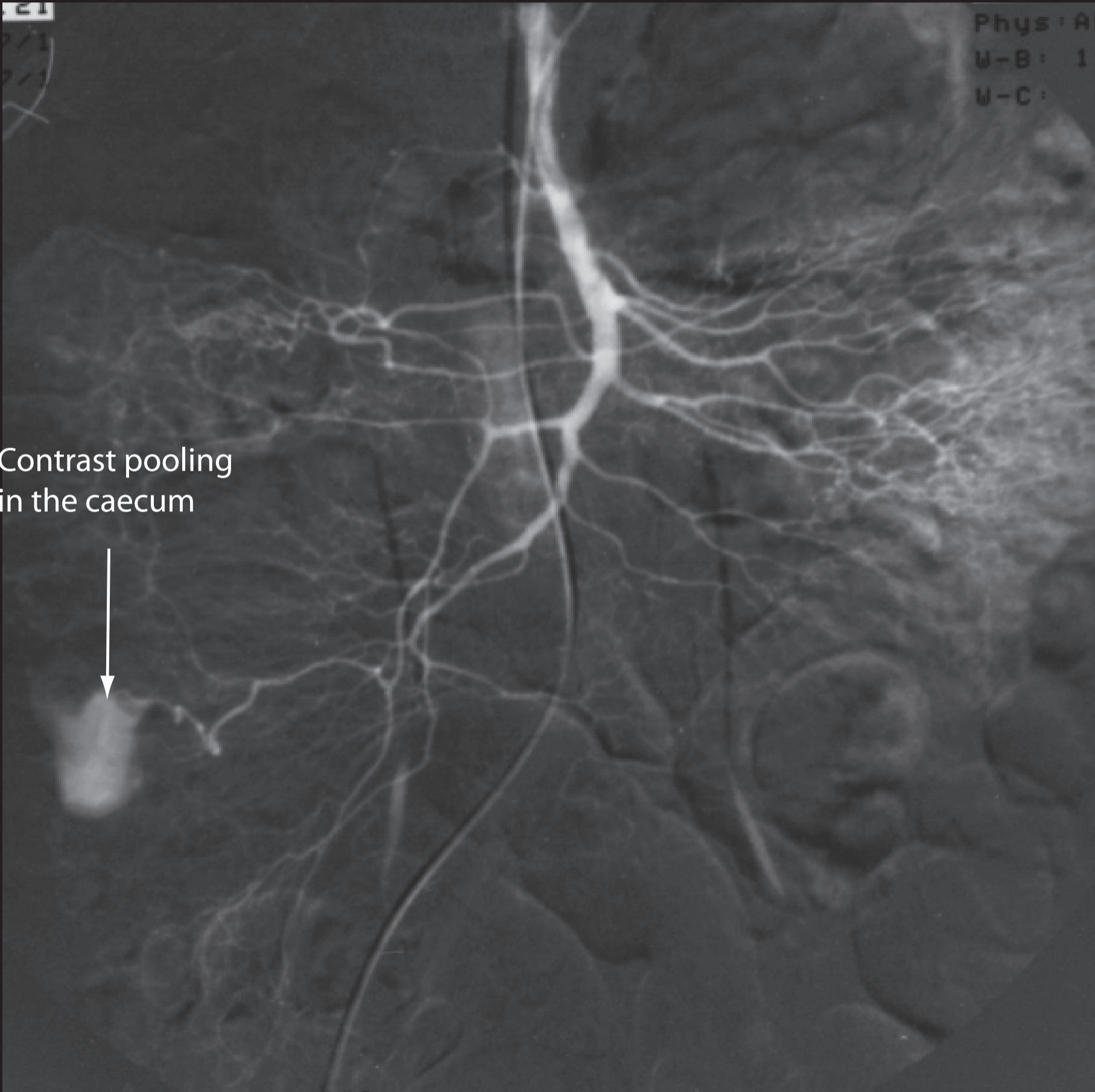


Selective superior mesenteric angiogram showing bleeding into caecum



Contrast pooling
in the caecum

